



PRESENTING CLINICAL SIGNS

History: Presented to ER yesterday for lethargy and anorexia. Today, laying in one spot all day and breathing heavier, as well as having black stool. Recently diagnosed with bone marrow disease, most likely due to septicemia and hypercytokinemia caused by Neisseria sp. Blood culture positive for Neisseria macacae, which is susceptible to Clavamox. Still has undulating fever.

DATE

5/27/22

ECHOCARDIOGRAPHIC FINDINGS

2D, M-mode, and Doppler study.

PERFORMED BY:

Tom McNeil

Left atrial size is normal. The mitral valve is normal. Left ventricular dimensions are normal. Left ventricular systolic function is normal. The aorta and aortic valve are normal. Right atrial and right ventricular dimensions are normal. The tricuspid valve is normal. The pulmonary artery and pulmonic are normal. No shunting lesions are visualized. No pericardial effusion or cardiac masses are seen.

INTERPRETED BY

Keith Blass, DVM,
MS, DACVIM
(Cardiology)

LA - 40.1 mm
LVIDd - 40.5 mm
LVIDs - 26.5 mm
FS - 34.6%
LVOT - 1.52 m/s
RVOT - 1.24 m/s

PATIENT

Maple Martin

SPECIES

Canine

ASSESSMENT/RECOMMENDATIONS

Normal echocardiogram

This examination demonstrates no evidence of primary cardiac disease or any endocarditic lesions. As such, there does not appear to be a cardiac contribution to Maple's persistent fever and other clinical signs.

BREED

German Shepherd

No therapy is recommended based on this exam.

A recheck echocardiogram is recommended if new physical exam and/or clinical abnormalities suggestive of the presence of structural heart disease develop.

SEX

FS

AGE

5 y

WEIGHT

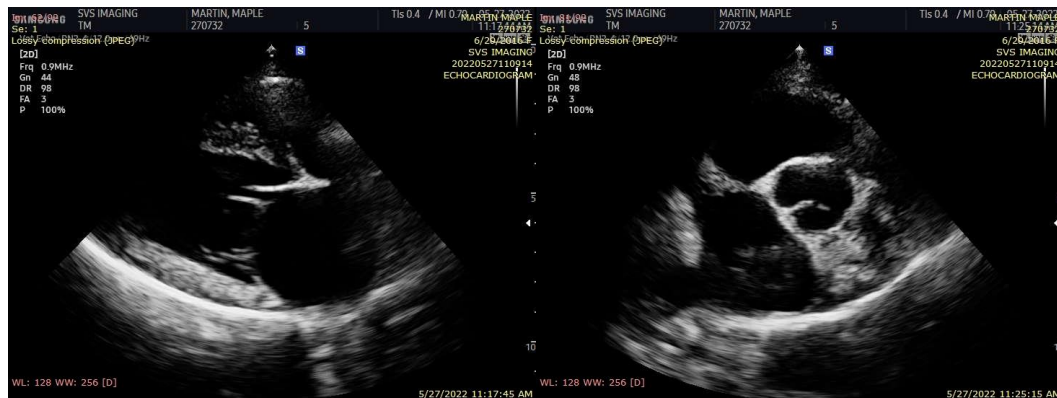
34.5 kg

HOSPITAL NAME

SVS Imaging CT

REFERRING VET

Dr. Bianco





DATE

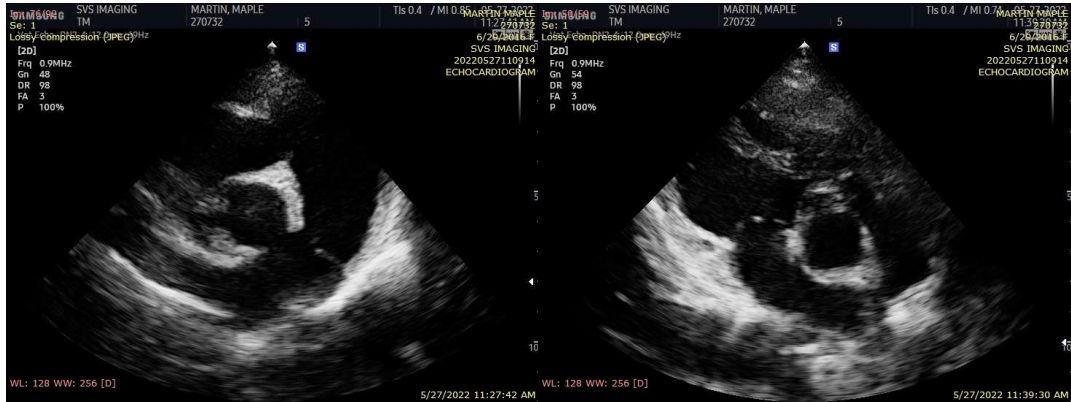
5/27/22

PERFORMED BY:

Tom McNeil

INTERPRETED BY

Keith Blass, DVM,
MS, DACVIM
(Cardiology)



The information and recommendations provided are based on the images presented by the referring veterinarian. No evaluation can be communicated regarding pathology that was not visible in the image/video clips provided.

Thank you for this referral. If the clinical or image interpretation does not parallel your findings or if I can be of any further assistance please contact me.

PATIENT

Maple Martin

Keith Blass, DVM, MS, DACVIM (Cardiology)
KeithBlass@gmail.com
631-804-5754

SPECIES

Canine

BREED

German Shepherd

SEX

FS

AGE

5 y

WEIGHT

34.5 kg

HOSPITAL NAME

SVS Imaging CT

REFERRING VET

Dr. Bianco